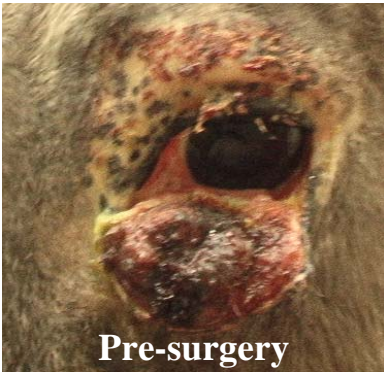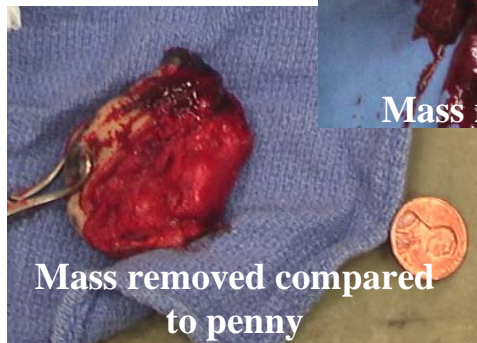

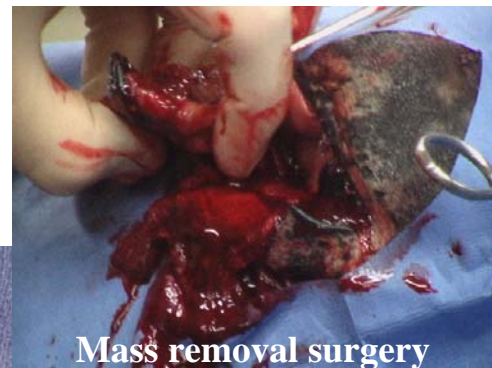


History: A 26 year old Appaloosa mare presented with a mass on the lower left eyelid. The result of the previous biopsy was a squamous cell carcinoma. The mass was frozen a couple of times in the previous to years by another DVM.

Physical Exam: The mass only involved the lower eyelid and not the third eyelid or the globe. With the size of the mass, surgery to remove the mass was elected as the treatment of choice.

Treatment: Surgery to remove the mass was performed under standing sedation and a local nerve block. The mare was sent home in an anti-inflammatory/pain killer, eye antibiotic ointment, and systemic antibiotics.



Prognosis: Due to the limited amount of tissue at the surgery site, it is probable that all of the cancer cells were not removed. Although the eyelid looks good and the response of surgery is favorable. The client was instructed to be diligent at evaluating the eyes on this mare. If the cancer returns, freezing of the cancer in the early stages is more beneficial at resolution.

